

HIPPO

Automatisierte präoperative Messung
der Hüftpositionierung und Beckenmorphologie

image
biopsy
lab



LCE-Winkel (Lateral Center Edge)

35°

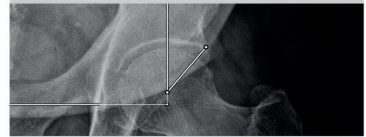
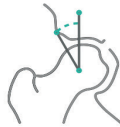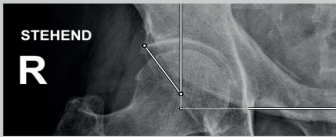
> 33° Überdeckung

Beschreibung¹⁾

22-33° Normal
< 22° Dysplasie
> 33° Überdeckung
> 40° Starke Überdeckung

39°

> 33° Überdeckung



CCD-Winkel (Corpus - Collum Diaphysen)

134°

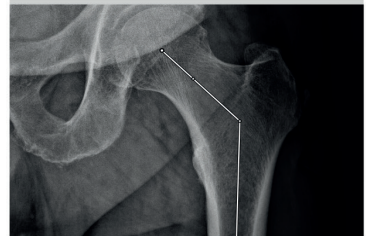
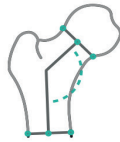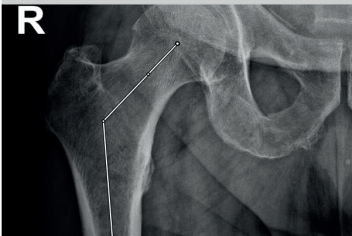
> 130° Coxa Valga

Beschreibung²⁾

120-130° Normal
< 120° Coxa Vara
> 130° Coxa Valga

133°

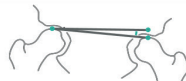> 130° Coxa Valga



Beckenschiefstand | Beinlängendifferenz

Beschreibung

< 3° Normal
3-6° Mild
> 6° Stark

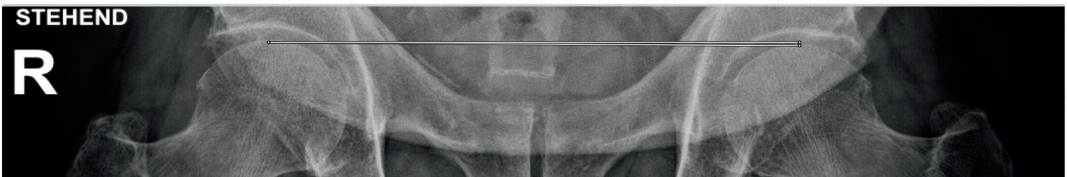


0° | 1mm *

< 3° Normal

STEHEND

R



© 2020 IB Lab GmbH | sales@imagebiopsy.com | www.ImageBiopsy.com